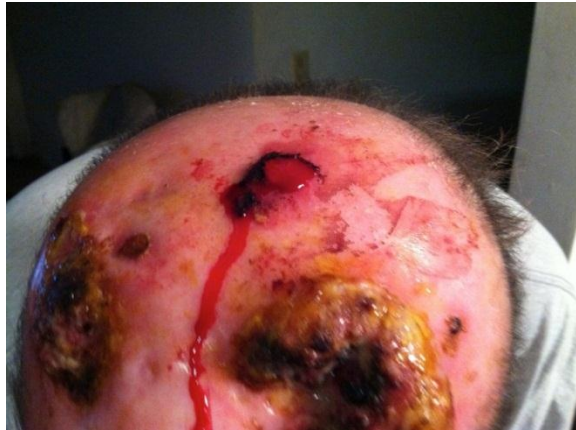
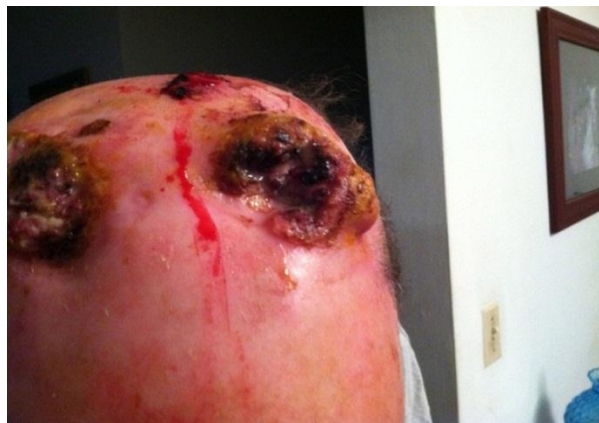
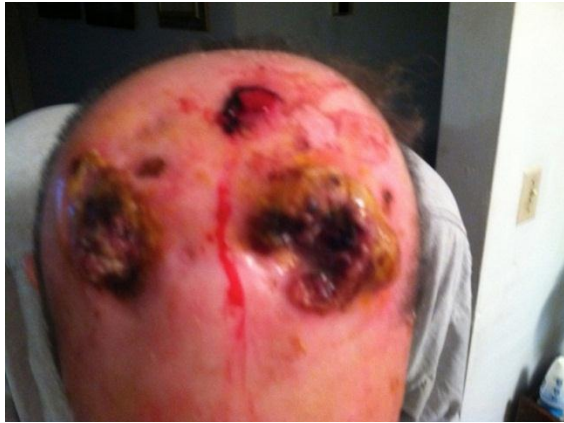The tumor on the left side of the head was the very large raised tumor with the holes seen in the original photo series. That tumor is now flat, scabbed and mostly gone. The large open cavity on the right is in the process of drying. Draw parallels with the photos of patient 2. The treatment progression includes bringing a tumor to the surface, progressively killing it, and then the affected area moves into the healing phase.

January 23, 2012 - Latest Pictures Received Below

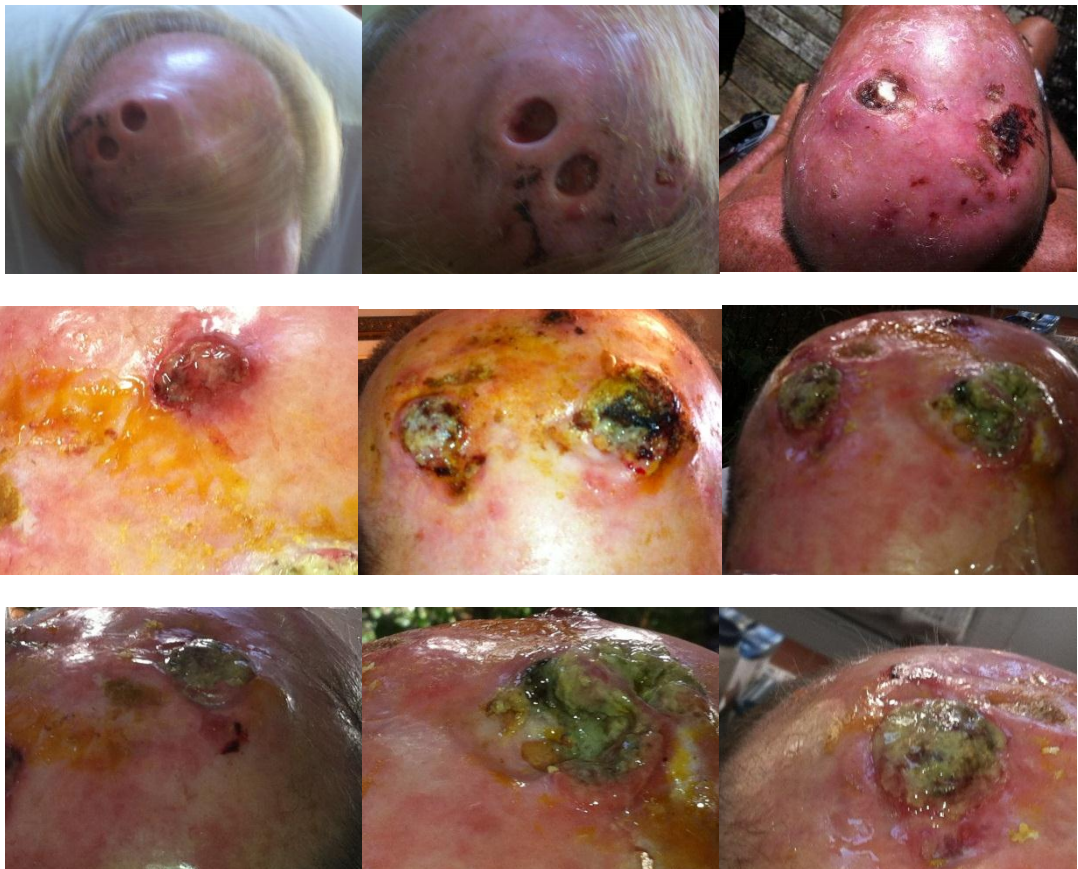

The first picture shows a large tumor protruding a few inches above the surface of the patient's skull prior to treatment. The cannabis-based extract was applied into the holes and the surrounding tissue that are seen in this patient's scalp that extended down to the skull. The second photograph shows the patient's head after receiving one of many radiation treatments. Subsequent photos demonstrate what appears to be the cannabis extract drawing out, and killing the cancer cells from these lesions.

While this patient's self-administered treatment with cannabis extracts is still in progress, the results after just two weeks of treatment are dramatic. Some of the tumors have disappeared and others have significantly shrunk to a fraction of their original size. Simultaneously, the patient has had a significant decrease in pain, improved sleeping (the 1st full night of sleep in 3 years), as well as relief from the symptoms of multiple sclerosis that the patient also suffers from. This self-treatment is a work in progress.

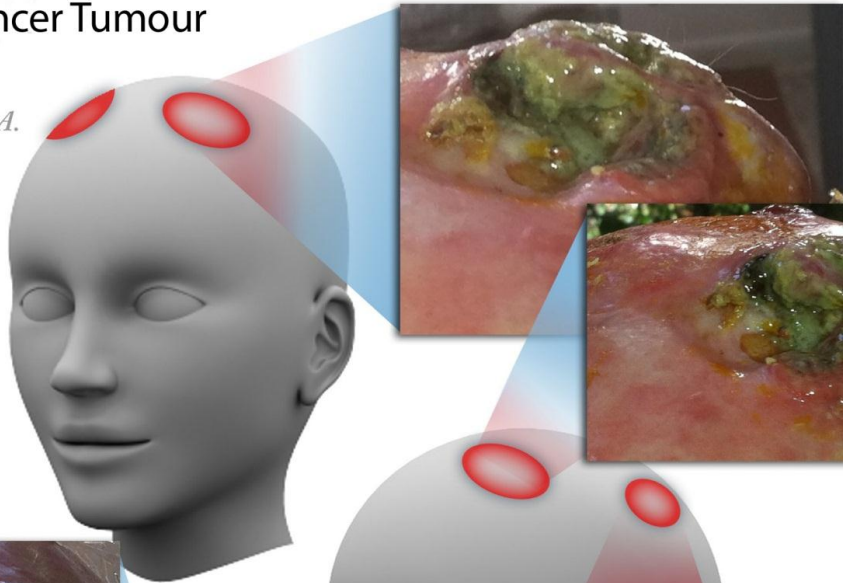
Cannabis Science is showing the general public unbiased evidence as we acquire it independent of the final outcome. As the treatment continues, and physician determinations are made, we will continue to update you so that you can follow the effectiveness of this treatment as it progresses.

January 11, 2012 - First Set of Images

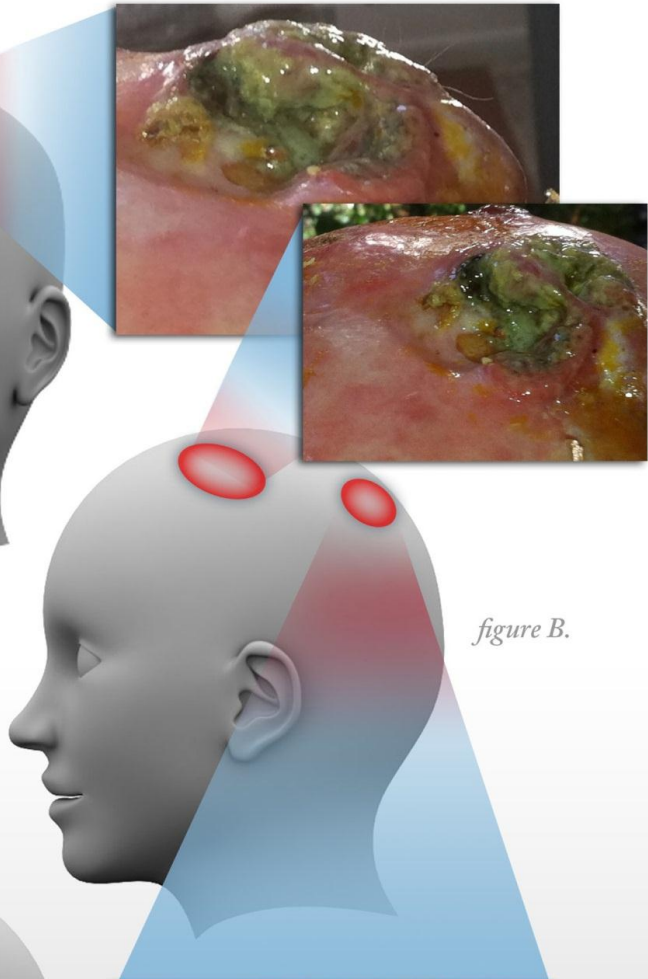


## Position of Cancer Tumour

*figure A.*



*figure B.*



*figure C.*

